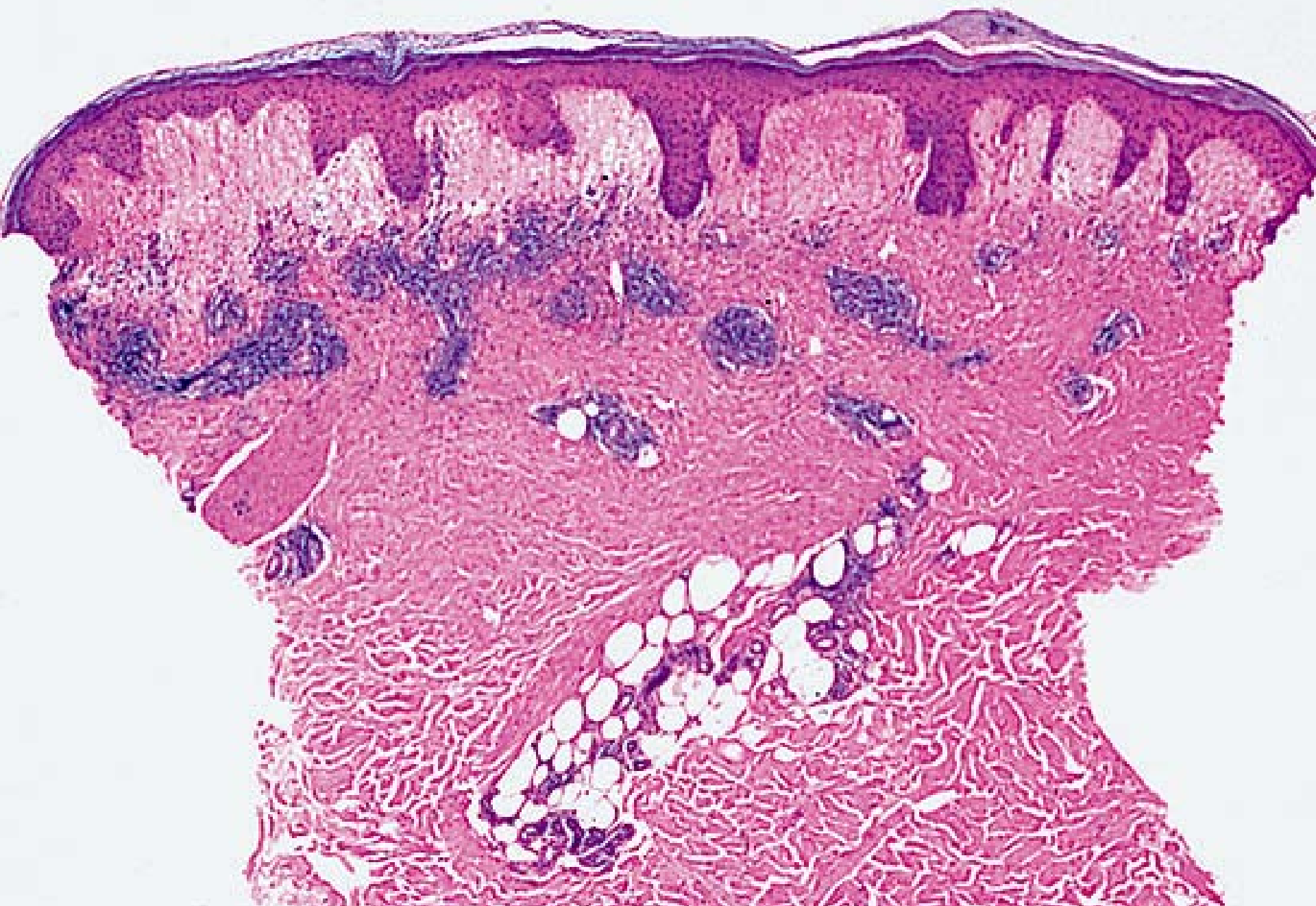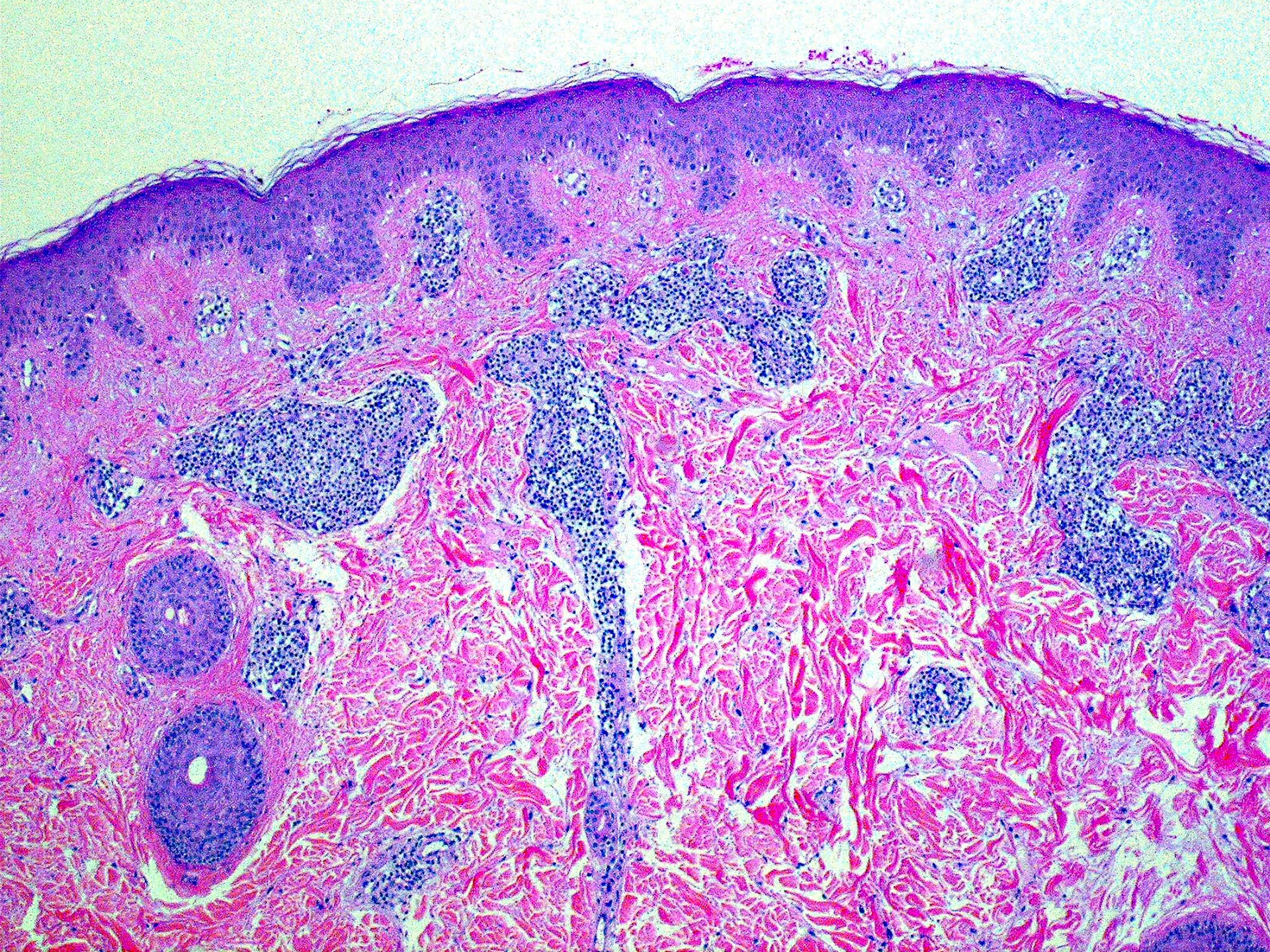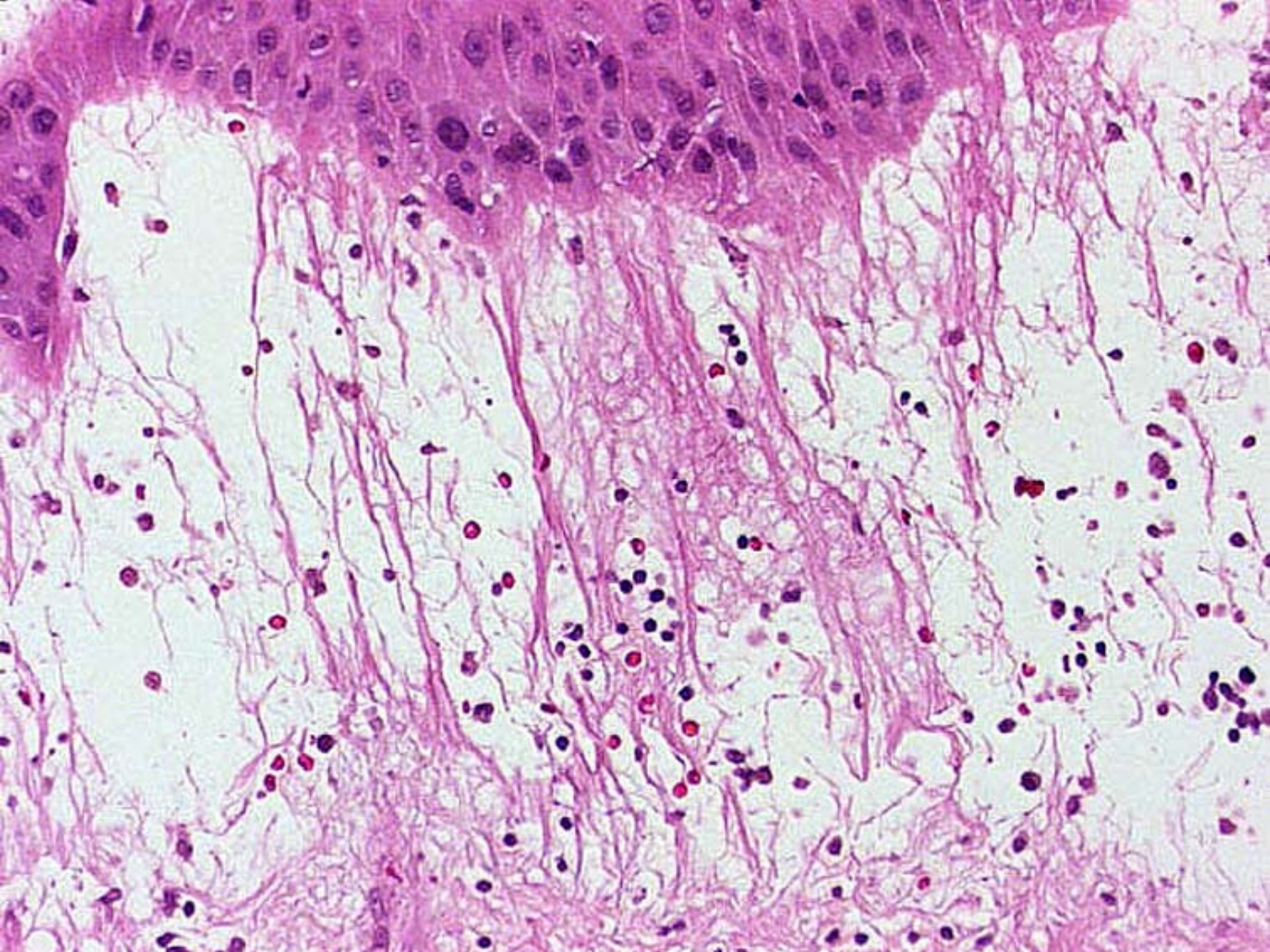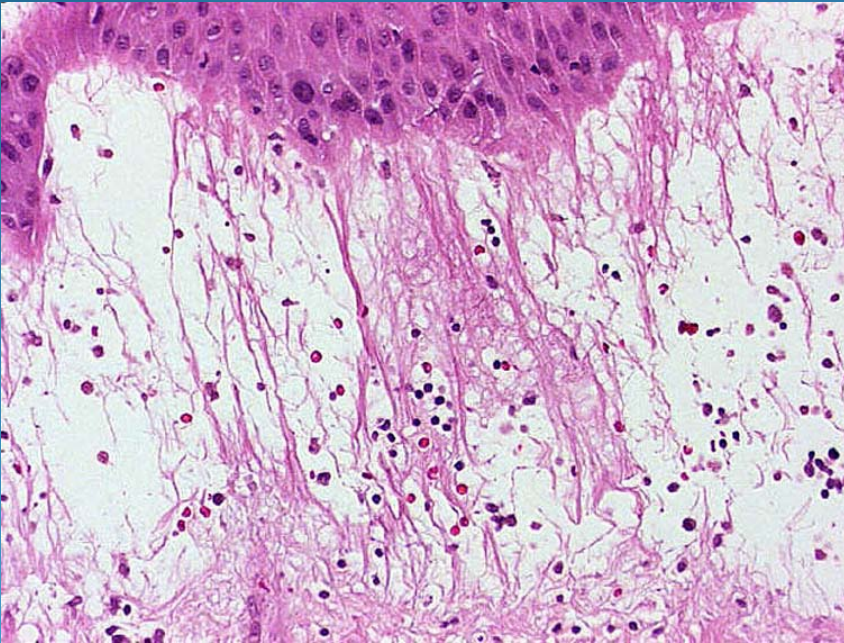


Polymorphous Light Eruption

Pearls



- Superficial and deep perivascular dermatitis
- May have extensive dermal edema forming papillary bulla